

Wernicke's Encephalopathy and Polyradiculoneurpathy after Bariatric Surgery: A Case Report

Osama A. Ragab^{1*}, Asmaa Abo El Fath Belal¹, Ayman M. Al-Malt¹, Nahla A. Nosair² and Ehab Shawky Mohamed¹

¹Neurology Department, Faculty of Medicine, Tanta University, Tanta-31527, Egypt

²Clinical Pathology Department, Faculty of Medicine, Kafr El-Sheikh University, Kafr El-Shaikh, Egypt

*Correspondence to:

Osama A. Ragab, MD
Neurology Department
Faculty of Medicine Tanta University
Al-Geish St., Tanta-31527, Egypt
Tel: +201117898368
E-mail: osama.ragab@med.tanta.edu.eg

Received: April 27, 2018

Accepted: June 13, 2018

Published: June 15, 2018

Citation: Ragab OA, Belal AAE, Al-Malt AM, Nosair NA, Mohamed ES. 2018. Wernicke's Encephalopathy and Polyradiculoneurpathy after Bariatric Surgery: A Case Report. *J Neurol Exp Neurosci* 4(1): 11-14.

Copyright: © 2018 Ragab et al. This is an Open Access article distributed under the terms of the Creative Commons Attribution 4.0 International License (CC-BY) (<http://creativecommons.org/licenses/by/4.0/>) which permits commercial use, including reproduction, adaptation, and distribution of the article provided the original author and source are credited.

Published by United Scientific Group

Abstract

Nutritional deficiency after bariatric surgery has its consequence on nervous system. Thiamine reduction occurs weeks after surgery, which results in dysfunction of both central and peripheral nervous system. We report a case of a young female patient who was subjected to bariatric surgery four months ago, then she developed ascending flaccid paresis due to polyradiculoneuropathy, facial diplegia and respiratory distress; these manifestations were preceded by ataxia and disturbed conscious level. After an initial diagnosis of Miller Fisher variant of Guillain-Barré Syndrome, the patient received two sessions of plasma exchange, then we revised our diagnosis based on clinical signs and brain imaging which was suggestive of Wernicke's encephalopathy. Consequently, we started thiamine infusion which resulted in improvement of both power and cognitive functions. Upon this case, we can deduce two key points: first, the importance of good nutritional support after bariatric surgery; second, the importance of considering nutritional deficiency as a differential diagnosis when facing any case with prior history of bariatric surgery.

Keywords

Bariatric surgery, Thiamine, Wernicke's encephalopathy, Polyradiculoneuropathy

Introduction

Neurological disturbances of both central and peripheral nervous system occur in approximately 5% to 16% of patients subjected to bariatric surgery. Inadequate nutritional follow-up, food avoidance, failure to take recommended dietary supplements and postoperative loss of appetite represent the major risk factors for developing neurological complications [1].

Thiamine (Vitamin B1) is a coenzyme involved in the metabolism of glucose, fatty acids and neurotransmitters. The incidence of Thiamine deficiency following bariatric surgery was approximately 18% [2]. As body stores of thiamine can be depleted in 6 weeks, most cases of thiamine deficiency related to neurologic manifestations including Wernicke's encephalopathy and polyneuropathy are presented two months post bariatric surgery [3]. Here, we report a female patient with Wernicke's encephalopathy and ascending flaccid paralysis resembling Guillain-Barré syndrome after laparoscopic sleeve gastrectomy.

Case Presentation

A single 22-year-old female patient (non-alcoholic) underwent bariatric

surgery four months ago, (her body mass index was 42 kg/m²) followed by dietary restriction; she lost about 40 kg. Five weeks ago, the patient's family noticed impaired concentration associated with unsteadiness while walking. The surgical team assured them as these symptoms are transient. One week later the patient lost her ability to walk because of weakness of both lower limbs; during the next day, the weakness involved the trunk, both upper limbs and facial muscles, associated with disorientation to time and persons.

On admission to our neurology department, the patient was drowsy with preservation and echolalia. There was bilateral horizontal and vertical nystagmus in primary position and gaze evoked in addition to limitation of upward gaze. Facial diplegia was evident and the motor system assessment revealed quadriparesis more proximal than distal (grade 2 proximal and 3 distal) on Medical Research Council grading. Deep tendon reflexes were absent all over, but the planter response was frank extensor on RT side and unelicited on LT side, abdominal reflex was bilaterally absent, no pathological reflexes could be elicited. The patient wasn't cooperative to evaluate sensation. Respiratory rate was 26 cycles/minute. Blood pressure was 105/70 mmHg and her heart rate was 93 beats/minute. On the other hand, her family confirmed that she was continent to both urine and stool till she was admitted. There was no history of other surgical or medical problems, or prior similar condition.

Arterial blood gases were in normal range, serum electrolytes including potassium were within normal ranges while complete blood count showed normocytic normochromic anemia (HB 11 gm/dl). Based on the presence of ascending flaccid paralysis and tachypnea which gave the initial diagnosis of Miller Fisher variant of Guillain-Barré syndrome, two sessions of plasma exchange were carried out urgently to avoid the risk of respiratory failure. Nerve conduction study revealed polyradiculoneuropathy (mixed axonal demyelinating and sensory-motor) affecting both upper and lower limbs (Figure 1). Her brain magnetic resonance image showed bilateral symmetrical hyperintensity caudate head, third ventricle borders and medial thalamic structures

head, third ventricle borders and medial thalamic structures (Figure 2). Echocardiogram was done, and the ejection fraction was 65% with no evidence of heart failure. Lumbar puncture was done with normal opening pressure and no cyto-albumin dissociation. Unfortunately, laboratory test for serum thiamine level detection is not available in any lab across our country.

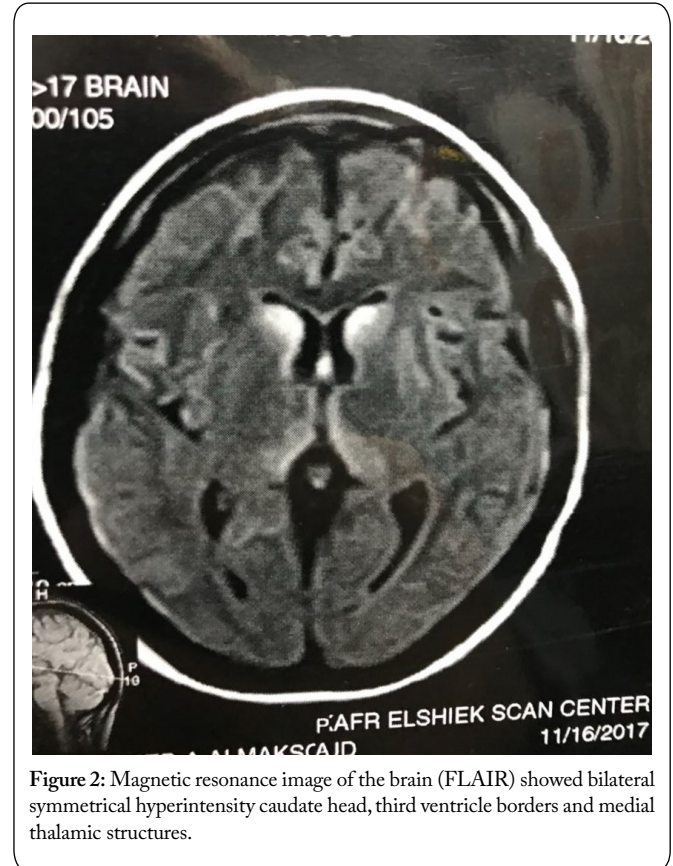


Figure 2: Magnetic resonance image of the brain (FLAIR) showed bilateral symmetrical hyperintensity caudate head, third ventricle borders and medial thalamic structures.

After an initial diagnosis of Miller Fisher variant of Guillain-Barré syndrome, we revised our diagnoses and the syndrome of Wernicke's encephalopathy and dry beriberi was assigned. We started thiamine intravenous infusion 500 mg TID for 5 days followed by 500 mg infusion once daily for another 5 days then she received 100 mg oral thiamine and we advised her to continue on therapy for 6 months. Three weeks later our patient showed marvelous improvement regarding her motor power. She regained the ability to walk unassisted, improved eye movement and became fully conscious and oriented.

Discussion

Bariatric surgeries are widely practiced all over the world for management of morbid obesity, with more than ten thousand surgeries performed annually in Egypt. However, diet restriction after these procedures may have dramatic consequences on both central and peripheral nervous system [4]. The literature had clarified the role of water soluble vitamins in the integrity of nervous system, and the neurological complication due to their deficiency after bariatric surgeries,

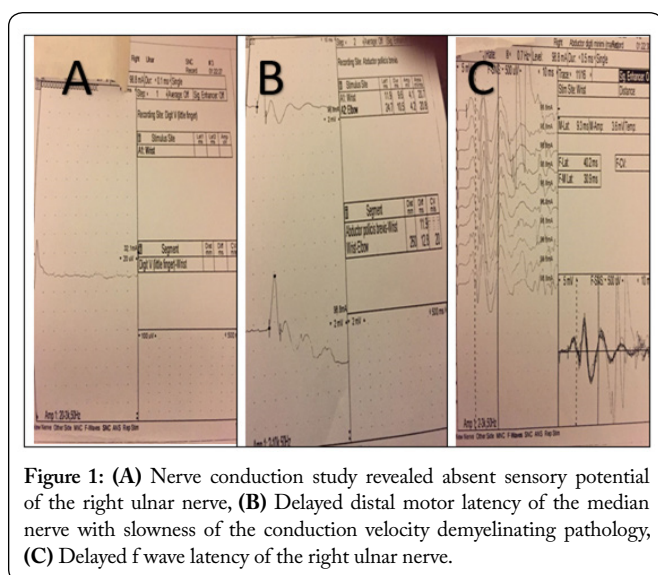


Figure 1: (A) Nerve conduction study revealed absent sensory potential of the right ulnar nerve, (B) Delayed distal motor latency of the median nerve with slowness of the conduction velocity demyelinating pathology, (C) Delayed f wave latency of the right ulnar nerve.

as thiamine deficiency, alters mitochondrial function by impairing oxidative metabolism resulting in death of selective neuronal cell [5]. Recent guidelines suggest a preventive thiamine supplementation for all patients undergoing bariatric surgery [6] only 10-20% of Wernicke's encephalopathy shows the typical clinical trial of altered mental state, cerebellar dysfunction and ophthalmoplegia even serum thiamine level may be normal in some cases [7]. Atypical neurologic features, including myoclonus, seizures, hearing loss, papilledema, paresis, and psychosis were reported [8]. So, a high level of suspicion should be present for proper diagnosis.

The presented case is a good illustration of thiamine deficiency inducing neurological disturbance with a clinical picture that was confusing with other familiar illnesses such as Guillain-Barré syndrome.

Thiamine body store is depleted from 4 to 12 weeks, so the neurological consequence of its deficiency is expected to occur at least one month after surgery [8]. Radiculoneuropathy with ascending paralysis affecting lower limbs, trunks then upper limbs have been reported with thiamine deficiency. It's usually axonal with no cerebrospinal fluid cyto-albumin dissociation [9]. In our case the early symptom was mild confusion followed by ataxia then limbs weakness, so as an initial diagnosis was Miller Fisher variant of Guillain-Barré syndrome. Hence the decision to start urgent plasma exchange was made as an urgent procedure to prevent respiratory failure. On the other hand, there were clinical signs which must be taken in consideration (disturbed conscious level, upward gaze palsy and the golden pyramidal sign of extensor planter response). Based on these signs brain magnetic resonance was done and the image showed bilateral symmetrical hyperintensity caudate head, third ventricle borders and medial thalamic structures. These findings are classical for Wernicke's encephalopathy. The nerve conduction studies revealed mixed axonal demyelinating polyradiculoneuropathy.

After these findings, we faced the famous question: what is the lesion? In fact, we have two hypotheses: one of them is its acute inflammatory polyradiculoneuropathy and co-incidental Wernicke's encephalopathy, while the other hypothesis assumed the one pathology diagnosis considering thiamine deficiency is responsible for the polyradiculoneuropathy and Wernicke's encephalopathy.

Of course, thiamine serum level will help answering this question, but unfortunately this test isn't available in any lab all over the country. Revising literature didn't require thiamine serum level as an essential criterion for diagnosis of Wernicke's encephalopathy or associated neuropathy.

Previous case reports of thiamine deficiency related to polyneuropathy showed axonal rather than demyelinating lesion [10-11]. On the contrary, our patient had both axonal and demyelinating features confirmed by electrodiagnostic study which means to expand the spectrum of Thiamine related neuropathy to include demyelination also.

Dias et al., reported two cases of inflammatory neuropathy after bariatric surgery; based on histopathological findings,

with no improvement on thiamine supplementation but after receiving intravenous immunoglobulin, neither of both cases showed signs of encephalopathy which is not the same situation in the present case [12]. So, we cannot overlook the possibility of inflammatory aetiology of neuropathy, but the one aetiology diagnosis was more reasonable in our case. Another case of Wernicke's encephalopathy and axonal polyneuropathy following dietary restriction for short period without previous exposure to bariatric surgery was reported by Liang et al., shed lights on the importance of early recognition of such cases and proper management [13].

Finally, we stopped plasma exchange and started intravenous thiamine infusion daily for five days followed by oral Thiamine intake which resulted in marvelous improvement of both cognition and motor power.

Conclusion

The present case illustrates the importance of a good nutritional support after bariatric surgery and the need for increasing awareness of both patients and surgeons to avoid these catastrophic neurological complications. Finally, neurologist must consider nutritional deficiency as a differential diagnosis when facing any case with prior history of bariatric surgery.

Acknowledgements

We would like to thank our decent patient for giving us a permission to report her case. Finally, we should thank Mrs. Hagar Aboelfath Belal for her help in editing this manuscript.

Conflict of Interest

The authors have no conflict of interest to be disclosed.

Compliance with Ethical Standards

Funding

The authors had not received any funds.

Informed consent

Informed consent was obtained from our decent patient to report her case.

This article does not contain any experimental procedure, so the approval of institutional ethical committee wasn't applicable.

References

1. Kumar N. 2014. Neurologic complications of bariatric surgery. *Continuum (Minneapolis)* 20(3): 580-597. <https://doi.org/10.1212/01.CON.0000450967.76452.f2>
2. Bal BS, Finelli FC, Shope TR, Koch TR. 2012. Nutritional deficiencies after bariatric surgery. *Nat Rev Endocrinol* 8(9): 544-556. <https://doi.org/10.1038/nrendo.2012.48>

3. PUNCHAI S, HANIPAH ZN, MEISTER KM, SCHAUER PR, BRETHAUER SA, et al. 2017. Neurologic manifestations of vitamin B deficiency after bariatric surgery. *Obes Surg* 27(8): 2079-2082. <https://doi.org/10.1007/s11695-017-2607-8>
4. ANGRISANI L, SANTONICOLA A, IOVINO P, VITIELLO A, ZUNDEL N, et al. 2017. Bariatric surgery and endoluminal procedures: IFSO Worldwide Survey 2014. *Obes Surg* 27(9): 2279-2289. <https://doi.org/10.1007/s11695-017-2666-x>
5. ABDYOU E, HAZELL AS. 2015. Thiamine deficiency: an update of pathophysiologic mechanisms and future therapeutic considerations. *Neurochem Res* 40(2): 353-361. <https://doi.org/10.1007/s11064-014-1430-z>
6. OUDMAN E, WIJNIA JW, VAN DAM M, BITER LU, POSTMA A. 2018. Preventing Wernicke encephalopathy after bariatric surgery. *Obes Surg* (In Press). <https://doi.org/10.1007/s11695-018-3262-4>
7. ARMSTRONG-JAVORS A, PRATT J, KHARASCH S. 2016. Wernicke encephalopathy in adolescents after bariatric surgery: case report and review. *Pediatrics* 138(6): e20161039.
8. SINGH S, KUMAR A. 2007. Wernicke encephalopathy after obesity surgery: a systematic review. *Neurology* 68(11): 807-811. <https://doi.org/10.1212/01.wnl.0000256812.29648.86>
9. RENTHAL W, MARIN-VALENCIA I, EVANS PA. 2014. Thiamine deficiency secondary to anorexia nervosa: an uncommon cause of peripheral neuropathy and Wernicke encephalopathy in adolescence. *Pediatr Neurol* 51(1): 100-103. <https://doi.org/10.1016/j.pediatrneurol.2014.03.025>
10. TOWBIN A, INGE TH, GARCIA VF, ROEHRIG HR, CLEMENTS RH, et al. 2004. Beriberi after gastric bypass surgery in adolescence. *J Pediatr* 145(2): 263-267. <https://doi.org/10.1016/j.jpeds.2004.04.051>
11. STROH C, MEYER F, MANGER T. 2014. Beriberi, a severe complication after metabolic surgery-review of the literature. *Obes Facts* 7(4): 246-252. <https://doi.org/10.1159/000366012>
12. DIAS JC, DE MEDEIROS VIDAL C, DE FREITAS MR. 2016. Inflammatory polyneuropathy after bariatric surgery: report of two cases. *J Neurol Disord* 4(4): 278. <https://doi.org/10.4172/2329-6895.1000278>
13. LIANG H, WU L, LIU LL, HAN J, ZHU J, et al. 2017. A case report: non-alcoholic Wernicke encephalopathy associated with polyneuropathy. *J Int Med Res* 45(6): 1794-1801. <https://doi.org/10.1177/0300060517699039>